



## From The Editor

Welcome to the TSG Winter Newsletter. Although Spring has sprung, it sure looks like Winter here in Big Sky, Montana. We are **Snowed In** and it is a perfect day to write the newsletter. In this issue, we present an interesting case of **neonatal herpetic encephalitis**. Neonatal herpetic encephalitis is not a common clinical presentation, but the failure to consider the diagnosis may result in dramatic morbidity

and mortality. Although uncommon, we have seen enough herpetic encephalitis-related litigation that we now offer an e-Learning course on the subject ■



## Introduction

Herpes simplex encephalitis (HSE) is a life-threatening infection of the central nervous system. It is an uncommon infection that causes necrosis and hemorrhage of the involved parts of the brain, killing the majority of untreated patients. Over the past few decades, polymerase

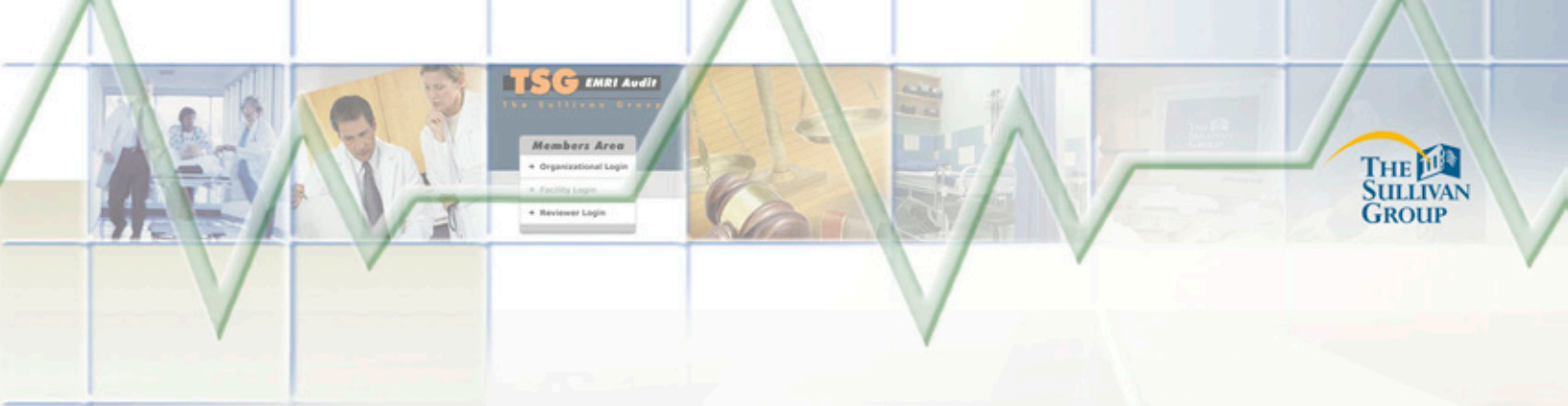
chain reaction (PCR) testing of cerebrospinal fluid has replaced brain biopsy as the gold standard for diagnostic testing, and the antiviral drug acyclovir has statistically reduced the mortality from 70% in untreated patients to 19% in treated patients.

Despite advances in diagnosis and therapy, HSE remains a serious quality and risk problem for practitioners in many specialties. Emergency physicians, primary care physicians, neonatologists, pediatricians, obstetricians, hospitalists, neurologists, and infectious disease specialists are all likely to encounter a patient with possible or proven HSE.

In malpractice cases involving HSE, one of two things has usually occurred; either the diagnosis was simply not considered, or acyclovir treatment was delayed or

## In This Issue...

From The Editor.....	Page 1
Introduction (Herpes Simplex Encephalitis) .....	Page 1
Pediatric Clinical Presentation .....	Page 2
Case Review .....	Page 2
Watch The Sullivan Group Impact Movie .....	Page 4
New e-Learning CME Courses.....	Page 9
What's New .....	Page 12
Upcoming Conferences .....	Page 13



never started. The end result was usually devastating disability or death.

In a review of medical literature and litigated cases, TSG has identified several common themes associated with the missed or delayed diagnosis and/or treatment of HSE:

- Practitioner unfamiliarity with this uncommon disease
- Late presentation to healthcare provider
- Non-specific clinical presentation
- Low index of suspicion
- Lack of definitive rapid diagnostic test
- Poor appreciation of the time-sensitive nature of the disease
- Lack of knowledge regarding appropriate treatment

## Pediatric Clinical Presentation

The literature offers scant data regarding the clinical presentation of HSE in children. In one review study, the symptoms of HSE in children ages 9 months to 16 years included:

- |                         |     |
|-------------------------|-----|
| ■ Fever                 | 79% |
| ■ Altered Consciousness | 68% |
| ■ Seizures              | 68% |
| ■ Vomiting              | 57% |

- |                      |     |
|----------------------|-----|
| ■ Headache           | 50% |
| ■ Personality Change | 43% |

From this list, it appears that fever is the most common presenting symptom of HSE in children, followed by altered consciousness and seizures. In infants, altered consciousness is usually much more subtle than in adults. Changes in newborn or infant behavior may include lethargy, irritability, poor feeding, and fussiness. In this age group, temperature instability can also occur.

## Key Point

The clinical presentation of HSE, particularly in neonates and infants, is not specific. Along with bacterial sepsis, HSE should be included in the differential diagnosis with symptoms of fever and changes in mental status or when complaints suggest a change from normal behavior.

## Case Review

### First ED Visit

Mom brought her 16-day-old infant girl, Caitlin, to the emergency department (ED) with the chief complaint of “possibly ill.”

### Nurse Assessment

The nurse recorded the initial history and assessment.



<b>Chief Complaint</b>	“Possibly ill” – per mother.
<b>History</b>	Mom voices concerns about baby not eating well and is not as awake as usual.
<b>Past History</b>	Vaginal delivery 5 weeks early. Birth weight 5 lb. 6 oz. No complications for mother or baby; both were discharged home the day after delivery. Taking formula with every feeding. No medications, allergies, surgeries, or other medical problems.
<b>Assessment</b>	<p>Pulse 180, Resp 48, Temp 98.4°F (36.9°C) rectal, Pulse ox 98%. Weight 6lb. 4oz.</p> <p>Baby sleeping in mom’s arms. Opens eyes at intervals. Fontanel flat. Color normal, skin warm and dry. Cap refill &lt; 3 seconds. Mucous membranes moist. No drooling, flaring or retractions noted. Unlabored clear breath sounds. Normal S1 and S2. Bowel sounds present. Abdomen soft. Currently has wet diaper, and had small amount formed green-brown stool while checking rectal temp. Umbilical cord came off during diaper change.</p>

## Physical Exam

She was examined by the emergency physician, who documented her findings as follows:


<b>Vital Signs</b>	Temp 98.4°F (36.9°C) rectal, pulse 180, respirations 48.
<b>General Appearance</b>	16-day-old female, easily aroused. No inconsolability or lethargy.
<b>Skin</b>	Warm and dry. No cyanosis, pallor, or rash.
<b>HEENT</b>	Normocephalic. Fontanel flat. Pupils equal and reactive to light. Extraocular muscles intact. Ears & throat unremarkable. Oral mucosa is moist.
<b>Heart</b>	Regular rate and rhythm.
<b>Lungs</b>	Clear to auscultation without rales, wheeze, or rhonchi. No accessory muscle use, retractions, or evidence of respiratory distress.
<b>Abdomen</b>	Soft, nontender, with positive bowel sounds
<b>Extremities</b>	No edema. Moves all extremities.

Caitlin was then evaluated by the emergency physician.

## History

The ED physician recorded the following history.

<b>Chief Complaint</b>	Possibly ill.
<b>History</b>	16-day-old female with decreased intake today. No BM for 48 hours. No difficulty breathing, but slight upper airway congestion. No vomiting, cough, or fever.
<b>Past History</b>	None.
<b>Medications</b>	None.
<b>Review Of Systems</b>	Five weeks premature and a normal vaginal delivery. Otherwise negative.



**Editor’s Note:** *The physician did not document a neurologic exam. This is a key element of the physical examination in every newborn. Considering the ultimate outcome in this case, this could become a significant issue.*

## ED Course and Medical Decision-Making

The medical decision-making documented by the emergency physician was brief and to



the point (maybe a bit too brief). He charted, "This is a well appearing child with a normal pulse oximetry, and I do not feel that further workup is necessary at this time." The impression was mild upper respiratory congestion and mild constipation. His instructions to the mother were, "See the pediatrician in 2 days if not better. If worse at all or the condition changes, return to the ED."

Upon discharge, the nurse noted, "Mom voices her understanding of the plan to return home with the baby, and to follow up with the pediatrician as discussed. The baby is now sleeping in mom's arms. No drooling, flaring, or retractions noted. Mom will discuss feedings with pediatrician."

**Editor's Note:** Before moving on to the second ED visit, let's consider the salient issues regarding the child's presentation and management during the first ED visit. Considering all the facts above, what do you consider to be the one key element of the child's presentation?

*"Mom voices concerns about baby not eating well and is not as awake as usual."*

*The child was only 16 days of age, but she had already established a sleeping and eating pattern. Mom noticed a change in this pattern. If there was any possibility of establishing the requisite threshold for concern, it was in mom's observation. There may never be rock solid evidenced-based guidance given this and similar neonatal presentations. The fact is that mom was concerned, and mom was right; this child was sleeping more and eating less.*

*The physician does not seem to have identified anything in the history or the physical that would raise the red flag. But reference to the nursing note and perhaps asking the question, "What exactly did you mean by that?" may have elicited additional key information or caused the practitioner to consider further evaluation or consultation.*

*Also, considering the issue of eating and sleeping, the physician should have considered the neurologic exam to be high yield and an absolute necessity. If it was done, it should have been documented. TSG research on 'documentation of the relevant organ system' demonstrates that the neurologic examination is the exam that is most often missing.*

**Let's move on to the second visit.**

Watch this 3-Minute Movie to Learn More about The Sullivan Group & their EMRI Program.





## Second ED Visit

Fourteen hours after discharge from the first ED visit, Caitlin's mother took her to a second ED at a different hospital.

### Triage and Nurse History

<b>Chief Complaint</b>	Carried in by mother, who states that Caitlin is "sick" for 3 days. No vomiting or diarrhea.
<b>History</b>	Mild cough and decreased oral intake. Was seen at another ED early this morning and was told she had a cold.
<b>Past History</b>	5 weeks early delivery. Normal pregnancy, normal birth.
<b>Assessment</b>	Pulse 162, Resp 36, Temp 98°F (36.7°C) rectal, Pulse ox 98% on room air. Weight 6 lb. 5½ oz. Baby lying on ED cart with weak cry. Mother states decreased oral intake. Lungs clear. Abdomen soft, bowel sounds present.

Caitlin was promptly evaluated by the emergency physician who dictated a detailed note.

### History

<b>Chief Complaint</b>	Cough.
<b>History</b>	16-day-old female infant brought in by her mother with complaint of being ill for about 3 days. Started with fussiness and slight cough, now is progressively worse with poor oral intake. Mom thinks there might be brief spells of apnea. No vomiting, diarrhea, fall, or injury. She was seen at another hospital ED earlier today.

<b>Past History</b>	Born 5 weeks premature but no mechanical ventilation needed. Mother had premature labor starting at 25 weeks gestation. There is a question of maternal group B strep infection, but this cannot be confirmed.
<b>Medications</b>	None.
<b>Review Of Systems</b>	Not much history of cough. No rash, vomiting, diarrhea, fall, or injury. She has been voiding. Other systems reviewed and negative.

### Physical Exam

<b>Vital Signs</b>	Temp 98°F (36.7°C) rectal, pulse 162, respirations 36. Pulse ox 98% room air.
<b>General Appearance</b>	Child looks lethargic.
<b>Skin</b>	Slightly pale with delayed capillary refill. No rashes.
<b>HEENT</b>	Anterior fontanel is normal, not bulging or depressed. No signs of trauma. Mouth and pharynx normal. Mucous membranes moist. TMs are normal.
<b>Neck</b>	No lymphadenopathy. Child's neck is supple, but that is not very meaningful in this age group.
<b>Heart</b>	Normal with no murmurs.
<b>Lungs</b>	Clear with no retractions.
<b>Abdomen</b>	Soft, no obvious tenderness. Bowel sounds present.
<b>Genitourinary</b>	External examination is normal.
<b>Extremities</b>	No edema. Moves all extremities.
<b>Neurological</b>	Child is lethargic. PERRL. Does have some muscle tone with no focal neurologic signs. Barely whimpers when blood is drawn.



## Emergency Department Course

It was immediately recognized that this infant was pale, lethargic, and ill. She was placed on a cardiac monitor that showed sinus rhythm with rates between 160 and 170. A peripheral IV was started and a bolus of 20 cc/kg normal saline was given followed by 12 cc/hour maintenance. Since there was no cyanosis or respiratory distress and ABG results were adequate, no airway interventions were done. A lumbar puncture was performed. The possibility of serious bacterial infection was clearly considered, so empiric cefotaxime 150 mg and ampicillin 150 mg were administered IV.

The emergency physician documented, "It is really hard to know what is causing this. I have worked her up for sepsis, but there is no obvious pneumonia or UTI. It is unlikely the CSF is going to be positive. Hypoglycemia and acute cardiopulmonary disorder have been ruled out. I also considered a metabolic abnormality due to her low sodium. We did not do a CT as it was felt this would be low yield at this point. She has been treated for sepsis, and remains lethargic but stable for transfer."

**Editor's Note:** *At this point, it is apparent that something is very wrong. Everything has now changed. The issue is no longer early recognition through nuances in the child's presentation; it is creating an appropriate differential and intervening as quickly as possible. What is 'reasonable under the circumstances' is truly a moving target that can change from hour to hour.*

## Diagnostic Test Results

Radiology and lab studies were obtained in the ED.

<b>CBC</b>	WBC 9,900 with 52 segs, 38 lymphs, 7 bands. Hemoglobin 12.9, platelets 489,000.
<b>Electrolytes</b>	Glucose 80, sodium 126, potassium 4.4, chloride 91, bicarb 18, magnesium 1.7, calcium 9.3, BUN 11, creatinine 0.4.
<b>ABGs</b>	On 100% mask: pH 7.45, pCO2 32, pO2 291, bicarb 22, saturation 100%.
<b>Chest X-Ray</b>	Poor inspiration. No obvious infiltrate or active chest disease.
<b>Urinalysis</b>	Cath specimen. Results negative. Specific gravity 1.020.
<b>Cerebrospinal Fluid</b>	Performed on Tube #3. Red fluid. CSF glucose 46. Protein 1145 (normal 15-45). RBC 68, WBC 33, with 86% lymphocytes.
<b>Blood Culture</b>	Pending.

**Editor's Note:** *How do you remove CNS from the differential diagnosis? It seems that CNS should be at the top of the list until proven otherwise. The CSF results certainly don't rule out infection.*



*It is interesting that regardless of the medical decision-making statement, the physician started antibiotics that would cover birth-related CNS pathogens. If CNS is a consideration, which pathogens should the practitioner consider? Should it be limited to Group B Strep and Listeria? Should herpes encephalitis be a consideration?*

### Neonatology Consultation

Neonatology consultation was obtained during this second ED visit. The neonatologist obtained the additional history that the pregnancy was complicated by premature labor and that the mother had received prenatal steroids. She was also treated with antibiotics prior to delivery for a positive group B strep culture.



**Editor's Note:** *That is a key piece of information that the emergency practitioner should have elicited or documented as a pertinent negative. Go back for a moment to ED visit #1. The emergency physician did not specifically address the Group B Strep issue.*

The neonatologist agreed with the diagnostic evaluation and that Caitlin was lethargic. He was concerned about the low sodium and the possibility of sepsis. After conferring with the emergency physician and the mother, Caitlin was transported to the nearest tertiary pediatric medical center.

### Tertiary Care

At the pediatric hospital, supportive care was continued, and intravenous acyclovir was started in the ED. During the hospital course, diagnostic testing of the CSF by PCR was positive for herpes simplex. CNS imaging was also consistent with herpes encephalitis. Her clinical course continued to deteriorate despite the administration of IV acyclovir; she died 6 weeks later.


**"Your case based educational method is an outstanding tool to help learn how to avoid these emergency medicine pitfalls and provide high quality care to my patients. Thanks for a great product."**

*Kenneth Schepke  
JFK MEDICAL CENTER*



## The Legal Complaint

The child's parents filed a claim alleging medical negligence against the two community hospitals, the pediatric hospital, and nearly all of the physicians involved in the evaluation and treatment of this infant; this included the delivering obstetrician, the emergency physicians at both community hospitals, and numerous physicians at the pediatric hospital.



The main allegation was that all defendants failed

to recognize, diagnose, and treat herpes infection in this infant. A pediatric emergency physician reviewed the case on behalf of the plaintiffs, and opined that the defendants fell below the acceptable standards of care in the treatment of Caitlin by failing to timely diagnose and treat herpes infection, and that as a result of the negligence, she suffered neurological injuries resulting in her death.

Along with other parties involved in the case, the deposition of the plaintiff's pediatric emergency physician expert was

taken. He offered varying opinions about the standard of care in relation to the physician defendants.

## Expert Testimony

The actual plaintiff's expert testimony is presented at length in TSG's e-Learning course "[Herpes Simplex Encephalitis](#)." To summarize, the physician expert provided the following opinions during his deposition testimony:

- Seizures and fever are common presenting symptoms.
- Many neonates have no history of exposure to herpes.
- Non-specific symptoms in a neonate may necessitate a sepsis workup.
- Despite the absence of fever, seizures, or herpes exposure, this infant deserved a septic workup and empiric acyclovir along with antibiotics.
- The combination of prematurity, a Group B strep positive mother, and history of poor feeding necessitated admission for sepsis workup following the first ED visit.
- You do not wait for CSF results to treat with empiric acyclovir.
- Contraindications of acyclovir are few.

The list of opinions above shares similarities with the allegations seen in other malpractice cases involving neonatal HSE.



The defendant emergency physician, Dr. A, who had the first contact with Caitlin on day 16 of life, also gave his deposition. The plaintiff's attorney focused on the mother's observations, the nursing notes, the physician's failure to obtain a history of exposure to maternal pathogens, and the lack of a neurologic examination during the deposition of the ED physician. His testimony, supported by documentation in the medical record, was that Caitlin appeared well, was not febrile, had no seizure or focal findings, and was easily arousable and not lethargic. He felt that Caitlin had mild respiratory congestion and constipation, nothing more.

It was the defense position that Caitlin's initial presentation was so non-specific that the course of action undertaken by Dr. A was justifiable. It was felt that the symptoms and signs were insufficient for Dr. A to suspect sepsis or encephalitis. When Caitlin was taken to the second ED with a different presentation, all reasonable measures were undertaken by Dr. B and all subsequent treating providers.

After these and several additional depositions were obtained, the plaintiff dismissed the case. There seems to have been a reasonable basis for the case to continue, and the reason for dismissal is not clear. Typically,

## NEW e-Learning CME Courses

TSG has recently released the following new medical error and risk reduction courses, including our OB-Gyn courses listed below.

### Emergency Medicine Courses

- Acute Limb Ischemia
- Emergency Radiology: The Failure to Diagnose Upper Extremity Injuries
- Spinal Epidural Abscess Case Studies

### OB-Gyn Courses

- Ectopic Pregnancy
- Neonatal Asphyxia
- Postpartum Hemorrhage Part 1
- Postpartum Hemorrhage Part 2

a case involving a dead infant and some significant management issues does not result in a dismissal. Cases with far less merit and injury sometimes will often go all the way to a jury verdict.

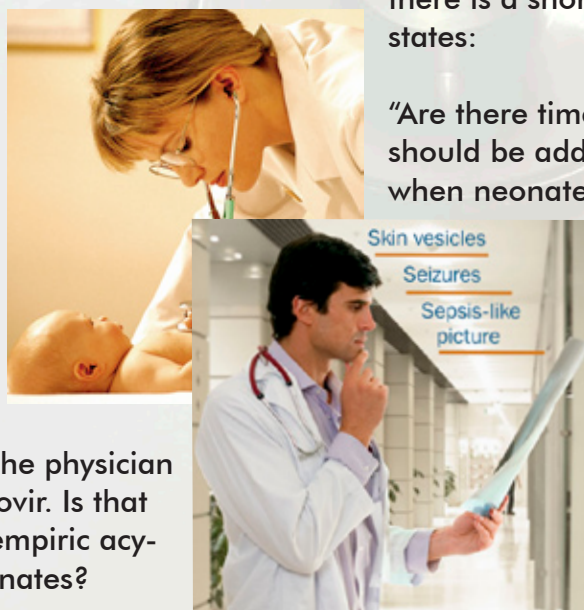We can only assume that the plaintiff's attorney felt his case was significantly weaker than that put forth by the defense.

## Acyclovir Discussion

There are a number of interesting lessons to be learned from this case. One of the critical issues related to patient safety is whether there is a role for empiric acyclovir therapy, and if so, in which patients. If this child had a chance, it was with early recognition of a significant clinical problem and then early intervention with acyclovir.

The plaintiff's expert testified that there was enough information on ED visit #1 for the physician to initiate empiric acyclovir. Is that correct? When should empiric acyclovir be utilized in neonates?

Review of the literature does not provide a definitive answer. There are no studies upon which definitive recommendations can be made. There are no systematic reviews; no double blind randomized trials; no meta analyses. There is one large retrospective study of 10,000 neonatal admissions over a 5-year period (Caviness, et al.); it describes only 10 neonates with herpes simplex infection. Thus, the recommendations from the



literature and texts are efforts to establish best practice based on very limited information.

In an editorial following the Caviness article, the author specifically addressed the question: "When should you initiate acyclovir therapy in a neonate?" He also specifically discusses variations in clinical practice when there is a shortfall of evidence. The author states:

"Are there times when parenteral acyclovir should be added empirically to antibiotics when neonates are admitted for rule-out sepsis? Certainly. Evaluation for herpes and administering acyclovir is appropriate when there is a clear index of suspicion because of the presence of skin vesicles, seizures, marked elevation of hepatic transaminases, a sepsis-like picture (including hypothermia), or simply when in the clinician's judgment the infant appears more ill than would be expected. A CSF pleocytosis with a mononuclear cell predominance outside of the enteroviral season also might be a time when evaluation and initiation of acyclovir are warranted."

The current edition of Rosen indicates that the issue of empiric treatment is controver-



sial because identification of infected infants is challenging. The recommendation is treatment in an ill or febrile infant under certain conditions:

- A history of maternal HSV infection
- Presence of vesicles on the skin
- Seizure
- Focal neurologic signs
- Consider its use in atypical presentations of sepsis or meningitis

Considering all of the above, it seems unlikely that the acyclovir-related criticisms of plaintiff's expert Dr. A hold water. The child does not appear to meet any of the criteria discussed above, and there certainly are no hard recommendations in the current literature. Regardless, it is always worth spending some time evaluating the state of the medical literature related to a critical high-risk subject area.

## Conclusion

Because of its infrequent occurrence, practitioners are not likely to be familiar with the spectrum of clinical presentation, diagnostic workup, and current treatment recommendations for herpes simplex encephalitis.

The most important fact to remember about HSE is that there is no pathognomonic clinical

presentation. Based on the symptoms and physical findings, the best you can do is to have a high degree of suspicion for HSE. You may feel like you are looking for a needle in a haystack, but remember that most patients who have HSE will present with a fever plus altered mental status or neurologic abnormalities. This is in contrast to meningitis patients, who may have a fever, but will also have meningeal signs and clear sensorium. That will obviously not be the case in the neonate and younger infants.

There are risk factors for HSE, including a history of past or current herpes infection or neonatal exposure by birth to a mother with herpes history. However, a key point is that most patients with HSE do not have identifiable risk factors. The suspicion for HSE should not be lowered when risk factors are absent.

Studies have established that most patients with proven HSE were not initially treated with acyclovir in the emergency department. Some of these patients had clinical presentations so obscure that encephalitis did not make the list of differential diagnoses. In retrospect, many of these patients did have sufficient symptoms and signs to warrant

*"The most important fact to remember about HSE is that there is no pathognomonic clinical presentation."*

## WHAT'S NEW

### TSG National Risk & Safety Collaborative

→ [Learn More](#)

### The Sullivan Group Clinical Rules for EMRs

→ [Learn More](#)

suspicion of encephalitis. Once encephalitis is on the list, practitioners are well served to weigh the potential risks and benefits of initiating prompt empiric therapy with acyclovir.

The recommendations for initiating acyclovir for possible cases for HSE have steadily strengthened over the past decade. Practitioners must be aware of these treatment recommendations because they are being increasingly used against defendant clinicians in litigation related to herpes simplex encephalitis.

## References

Baringer J. "Herpes Simplex Infections of the Nervous System." *Neurol Clin.* 2008;26:657-674.

Benson P, Swadron S. "Empiric Acyclovir Is Infrequently Initiated in the Emergency Department to Patients Ultimately Diagnosed With Encephalitis." *Ann Emerg Med.* 2006;47:100-105.

Caviness AC, Demmler GJ, Almendarez Y, Selwyn BJ. "The prevalence of neonatal herpes simplex viral infection compared with serious bacterial illness in hospitalized neonates." *J Pediatr.* 2008;153:164-9.

Hafner JW, Parrish SE, Hubler JR, Sullivan DJ/University of Illinois College of Medicine at Peoria, Peoria, IL; The Sullivan Group; Cook County Hospital/Rush Medical College. "Quality in Emergency Department Care: Results of the Sullivan Group's Emergency Medicine Risk Initiative National Audit." Abstract # 211 in *Annals of Emergency Medicine.* Vol. 36 Issue 3; September 2005.

Kesson A. "Management of Neonatal Herpes Simplex Virus Infection." *Paediatr Drugs.* 2001;3(2):81-90.

Kimberlin D. Editorial. "When Should You Initiate Acyclovir Therapy in a Neonate?" *The Journal of Pediatrics.* August 2008.

Kimberlin D. "Management of HSV Encephalitis in Adults and Neonates: Diagnosis, Prognosis and Treatment." *Herpes.* 2007;14;11-16.

Kimberlin D, Lakeman F, Arvin A, et al. "Application of the Polymerase Chain Reaction to the Diagnosis and Management of Neonatal Herpes Simplex Virus Disease." *J Inf Dis.* 1996;174:1162-1167.

Marx. *Rosen's Emergency Medicine, 7th ed.*; CHAPTER 173 – "Neurologic Disorders."

Peters ML. "Suspected meningitis in the emergency department: Diagnosis and management." *Clin Pediatr Emerg Med.* 2003; 4: 186.

Whitley R. "Therapy of Herpes Virus Infections in Children." *Adv Exp Med Biol.* 2008;609:216-232.



## Upcoming Conferences

**1 ACOG 59th Annual Clinical Meeting**  
**Booth # 1242**  
Washington Convention Center, Washington, DC  
May 2 - May 4, 2011

**2 UCAOA Spring Convention**  
**Booth # 535**  
Hyatt Regency Chicago, Chicago, IL  
May 10 - May 12, 2011

**3 PIAA Medical Liability Conference**  
**Booth # 19**  
Westin Kierland Resort, Scottsdale, AZ  
May 11 - May 13, 2011

**We look forward to seeing you there!**

Once again, if you have had interesting cases, near misses, or crashes with an interesting fact pattern that would benefit our readers, give us a call at the contact numbers below.

Thank you ■

### CONTACT US



The Sullivan Group  
1 S. 450 Summit Avenue  
Suite 320  
Oakbrook Terrace, IL 60181

**Toll Free**  
866.633.7475

**Office**  
630.268.1188

**Fax**  
630.268.1122

[www.thesullivangroup.com](http://www.thesullivangroup.com)

**Proven Reduction  
in Medical Errors**

**Proven Reduction  
in Claims**